



Author: Renato Ambrósio Jr, MD,  
PhD, FWCRS, PCEO,  
Instituto de Ohos Renato Ambrósio,  
Rio de Janeiro, Brazil

# Haze after PRK for Mixed Astigmatism

A 28-year-old male patient presented with unclear blur in vision. His uncorrected visual acuity was 20/100-1 in the right eye and 20/30 in the left eye. He underwent a PRK surgery for mixed astigmatism three years ago with a refraction of +1.00 / -3.75 x 5° in the right eye and

+1.25 / -3.75 x 180° before surgery. Slit lamp-microscopy showed opaque spots on the cornea. Pentacam Cornea OCT examination revealed corneal haze in both eyes.

## Right eye

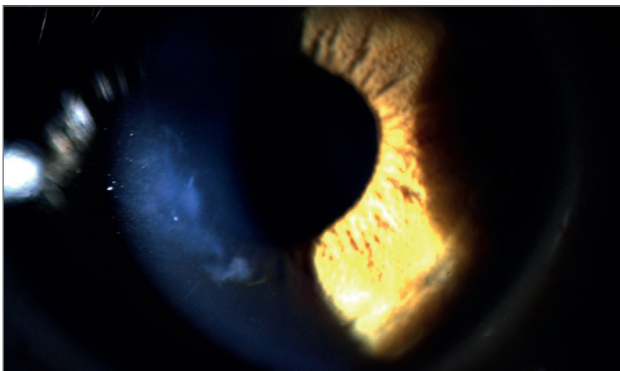


Fig 1: Slit-lamp microscopy of the right eye revealing opacifications of the cornea.

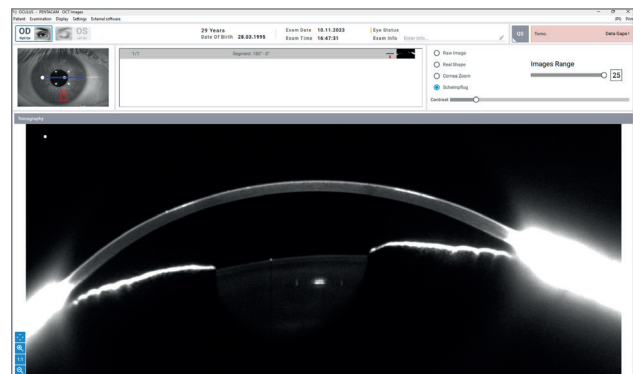


Fig 2: Pentacam Cornea OCT examination of the right eye with Scheimpflug image showing hyperreflective areas in the anterior cornea

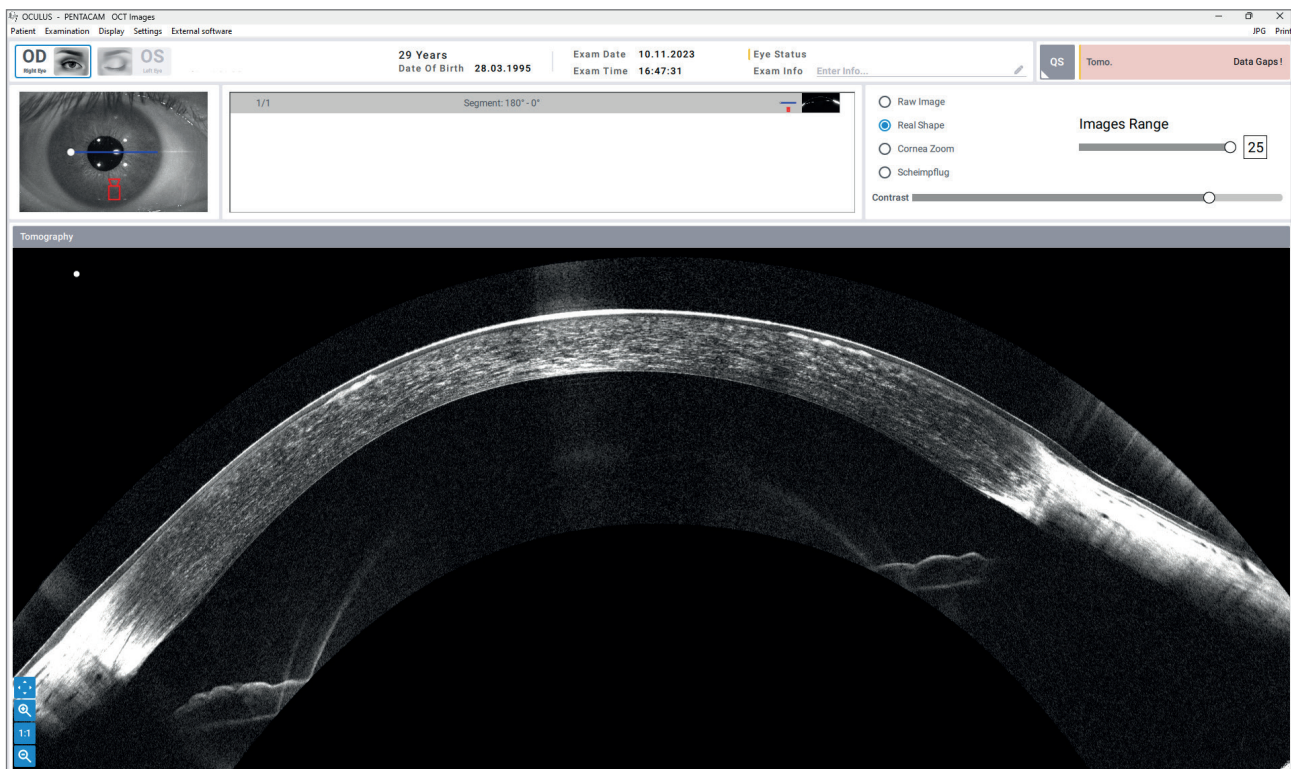


Fig 3: Real Shape image of the cornea showing changes in the corneal epithelium

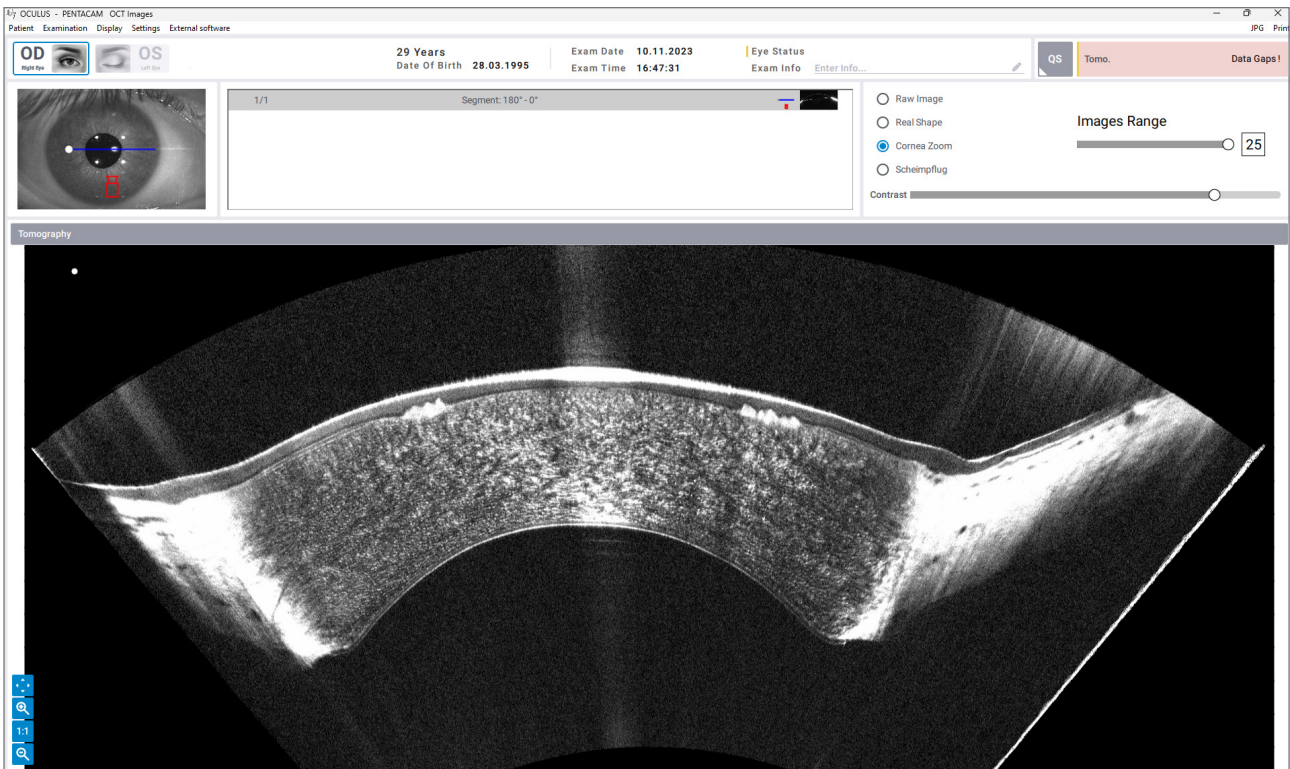


Fig 4: Cornea Zoom image showing the epithelial changes more detailed

Left eye

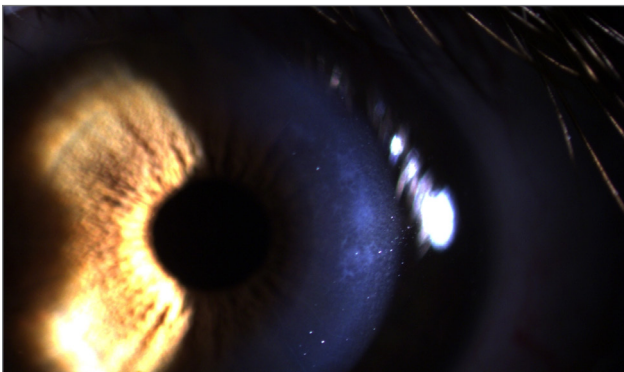


Fig 5: Slit-lamp microscopy of the left eye revealing opacifications of the cornea

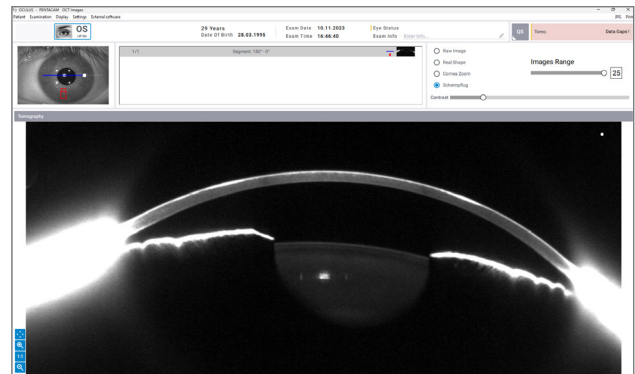


Fig 6: Pentacam Cornea OCT examination of the left eye with Scheimpflug image showing hyperreflective spots in the anterior cornea

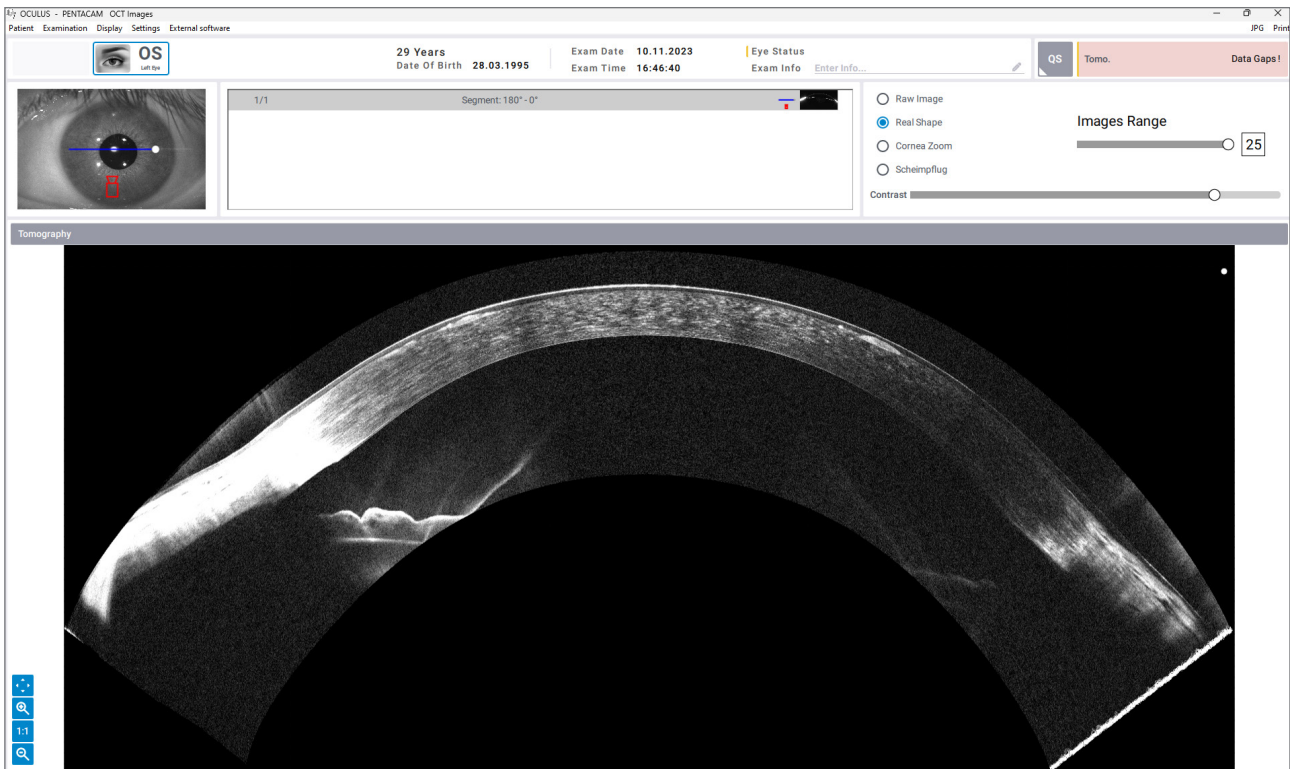


Fig 7: Real Shape image of the cornea showing changes in the corneal epithelium

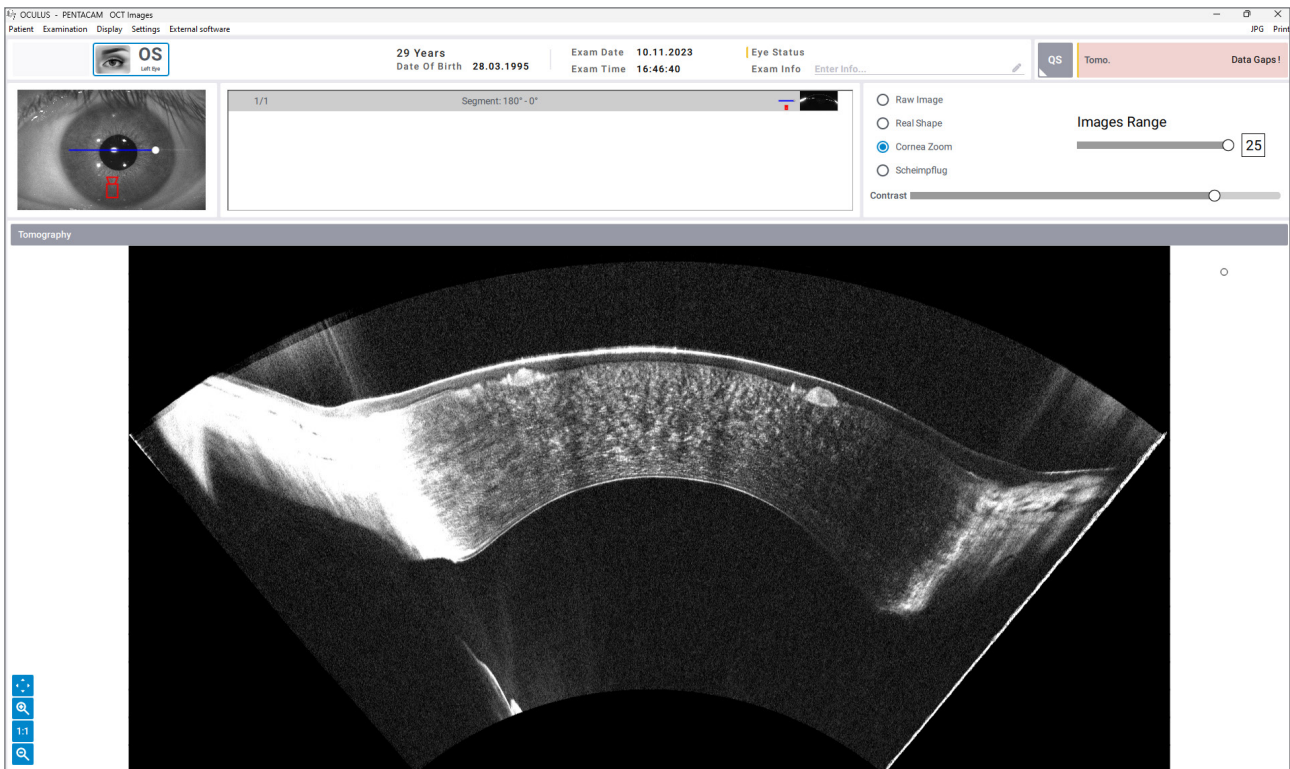


Fig 8: Cornea Zoom image showing the epithelial changes more detailed

A manifest refraction was performed and the visual acuity was increased to 20/25-1 with +0.75/-2.75 x 175° in the

right eye and to 20/20-1 with +0.75/-2.25 x 175° in the left eye. A new PRK was recommended.